

# TREATMENT OF HERNIATED LUMBAR DISC BY INTRADISCAL AND INTRAFORAMINAL OXYGEN-OZONE (O<sub>2</sub>-O<sub>3</sub>) INJECTION

M. MUTO<sup>(1)</sup>, C. ANDREULA<sup>(2)</sup>, M. LEONARDI<sup>(3)</sup>

(1) Neuroradiology OU, AORN Cardarelli, Naples, Italy.

(2) Neuroradiology OU, AO Consorziale, Bari, Italy.

(3) Neuroradiology OU, AORN Bellaria, Bologna, Italy.

## SUMMARY

**Material:** We report our experience between May 1996 and May 2003 with 2200 patients affected by low back pain or sciatica due to herniated disk treated by intradiscal and intraforaminal oxygen-ozone injection.

The patients received medical and physical therapy before treatment for at least 2 months; the patients with conus-cauda syndrome and hyperalgesic sciatica were excluded. We never performed discography before the treatment that was performed under CT guidance or fluoroscopy. CT provided monitoring of gas distribution in the disk and epidural space.

**Results:** No side effects were recorded at short and long-term follow-up. Clinical results were evaluated with the modified McNab method showing an 80% success rate and 20% failure rate in 1750 patients followed up to 6 months while the success rate dropped down at 75% and failure increased at 25% in 1400 followed up to 18 months. CT showed reduction in the size of the herniated disk in only 63% of the followed patients (420 patients).

The failure has been mostly related to: calcified herniated disk; spinal canal stenosis; recurrent herniated disk with epidural fibrosis; small descending herniated disk at the level of the lateral recess.

*Key words:* oxygen-ozone therapy, CT, Low back pain, sciatica.

## RÉSUMÉ

### **Le traitement des hernies discales lombaires par injection intradiscale et intraforaminale d'O<sub>2</sub>-O<sub>3</sub>**

**Matériel :** 2 200 patients souffrant de lombalgie ou sciatique en rapport avec une hernie discale ont été traités entre mai 1996 et mai 2003 par injection intradiscale et intraforaminale d'O<sub>2</sub>-O<sub>3</sub>. Tous les patients avaient bénéficié d'un traitement médical pendant au moins 2 mois. Les patients souffrant de syndrome de la queue de cheval ou de sciatique hyperalgique ont été exclus. L'injection d'O<sub>2</sub>-O<sub>3</sub> était faite sous contrôle scanographique ou scopique. La scanographie a permis de contrôler la distribution des gaz dans les espaces discal et extradural.

**Résultats :** Aucun effet secondaire n'a été observé. Les résultats cliniques ont été évalués selon la méthode de Mac Nab modifiée à 6 mois (1 750 patients suivis) et à 18 mois (1 400 patients suivis) les taux de succès ont été respectivement de 80 % et 75 %. L'examen scanographique a montré une réduction de la hauteur de disque de 63 % de patients suivis (n = 420). Les causes d'échec sont principalement les disques calcifiés, les canaux étroits, les récurrences de hernie avec filomes épидурaux, les petites hernies migrées dans le récessus latéral.

*Mots-clés :* ozone thérapie, scanographie, lombalgie, sciatique.

## INTRODUCTION

Nerve root pain and low back pain are one of the commonest conditions affecting the lumbar spine. Around 80% of the population in western countries will experience at least one episode of low back pain in their lifetime and 55% suffer from low back pain associated with radicular syndromes [14]. Back pain is often caused by disc disease even though other factors are responsible for nerve root syndromes and should be entertained when clinical symptoms fail to correlate with CT and/or MR findings [17].

In this paper, we report our experience between May 1996 and May 2003 with 2200 patients affected by low back pain or sciatica due to herniated disk treated by intradiscal and intraforaminal oxygen-ozone injection.

## MATERIAL AND METHODS

### **Material**

In the five-year period from January 1997 to May 2003, 2200 patients aged between 13 and 89 years underwent percutaneous chemonucleolysis with periradicular and pariganglionic injection of oxygen-ozone mixture.

The following selection criteria were adopted for inclusion:

- 1) clinical: low back and/or nerve root pain resistant to previous medical treatment, physiotherapy and other therapies (manipulation, acupuncture, etc.) for a period of not less than two months;
- 2) psychological: a firm resolve on the part of the patient to recover with a commitment to cooperate and undergo subsequent physiotherapy with postural and motor rehabilitation;
- 3) neurological: paresthesia or hypoesthesia over the dermatome involved, mild muscle weakness and signs of root-ganglion irritation;

4) neuroradiological (CT and/or MR): a) evidence of small and medium-sized herniated discs correlating with the patient's symptoms with or without degenerative disc-vertebra disease complicated by intervertebral disc changes (protrusion, herniation); b) residue of surgical (micro)-discectomy with herniation recurrence and/or hypertrophic fibrous scarring.

The exclusion criteria were:

- 1) CT/MR evidence of a herniated disc fragment with symptoms of motor and/or sphincter disturbance;
- 2) CT/MR evidence of disc herniation corresponding to clinically severe motor deficit and/or sphincter disturbance.

The indications for O<sub>2</sub>-O<sub>3</sub> treatment were extended to FBSS patients when it was understood that the ozone mechanisms of action could be exploited to treat the chronic inflammation and venous stasis present in FBSS. Technical approach to the disc is the same as that used for both discography and other percutaneous intervertebral

disc procedures. We used an 18-20G Chiba needle inserted from a posterior paravertebral oblique approach under CT or fluoroscopic guidance. The L5-S1 space is not always an easy target to reach and may require additional 30° craniocaudal inclination of the needle. Once the needle has been positioned in the centre of the disc, the gas mixture is injected into the disc (3-4ml) and into the epidural and intraforaminal spaces (10ml) at the concentrations of 30 micrograms/ml (figures 1 and 2).

We no longer perform discography before percutaneous treatment as the procedure adds no further diagnostic information needed for treatment. A CT scan is done before therapy to rule out the presence of a retro-psoas bowel loop.

CT guidance was adopted instead of the well-tested radiological monitoring by isocentric angio suite with double arm due to the need for meticulous positioning of the needle within the nucleus pulposus. In addition, CT avoids the use of intradiscal contrast administration which even in low doses

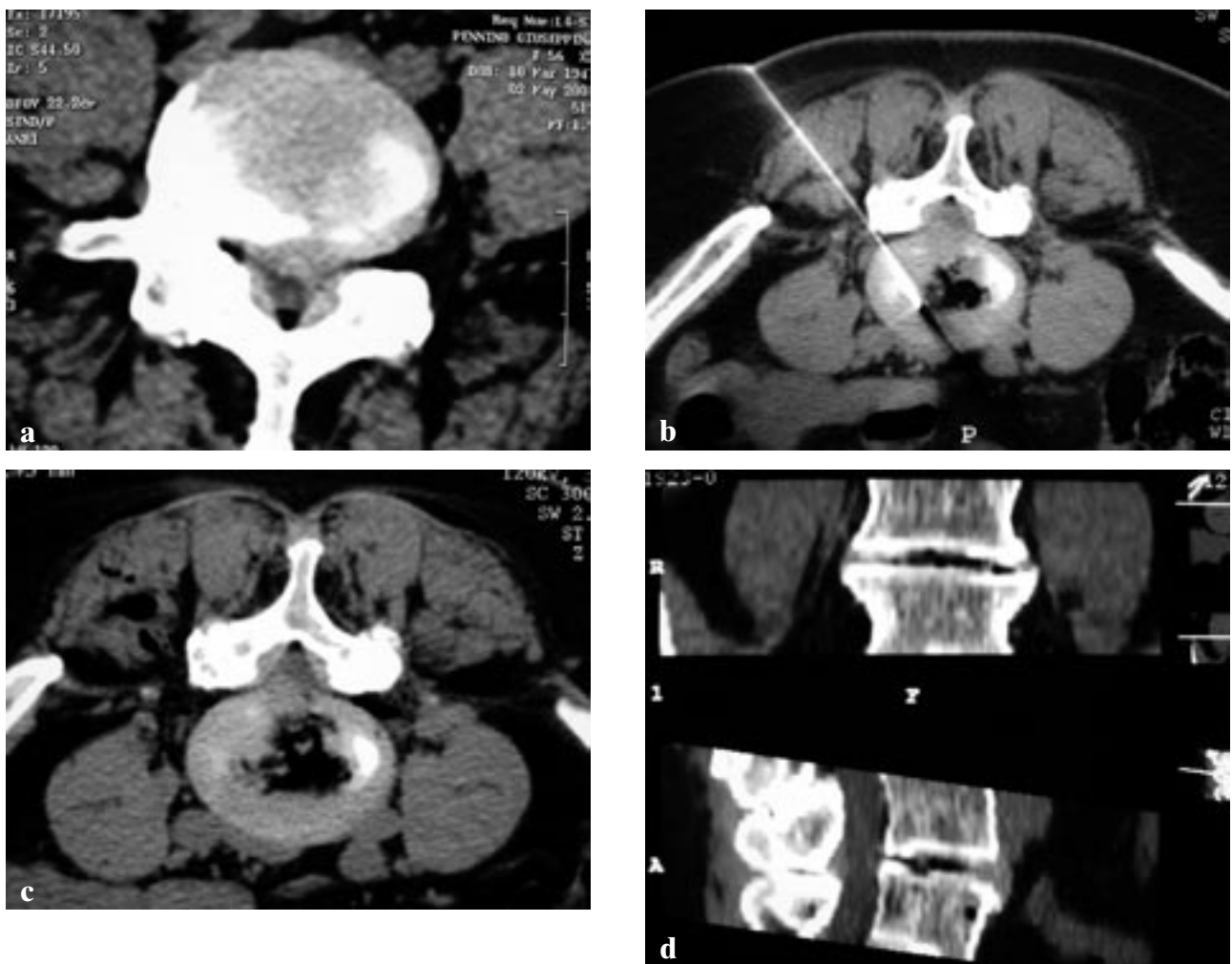

FIG. 1. – Patient with median and left paramedian L4-L5 herniated disk (a). Intradiscal positioning of the 20G Chiba needle under CT guidance (b). CT control after intradiscal injection of 4ml of oxygen ozone mixture (c) with evidence of intramuscular gas diffusion. Coronal and sagittal (d) MPR CT images with evidence of gas within the disk.

FIG. 1. – Hernie discale postérolatérale L4-L5 (a). Positionnement d'une aiguille de Chiba (20 G) sous scanographie (b). Contrôle scanographique après injection du mélange O<sub>2</sub>-O<sub>3</sub>, noter la diffusion moléculaire du gaz (c). Reformattage dans les plans frontal et sagittal montrant la présence de gaz dans le disque (d).

reduces the discal absorption of ozone and the space available and hinders the search for the site of intraforaminal injection of the  $O_2-O_3$  mixture.

A CT scan was always performed to confirm the intradiscal injection, and the epidural and intraforaminal diffusion of the  $O_2-O_3$  mixture.

### Methods

There are many and different protocols to analyze in an objective way the clinical results in patients with low back pain and HNP (16-18). We evaluated

our results according to a modified Mac Nab method (*table I*) in the following situations: degenerative disease complicated by herniated disk, L4-L5 or L5-S1 herniated discs, multiple disc herniations, FBSS, calcified disc herniations and disc herniations associated with spinal stenosis.

The first three situations represented 78% of all treated patients. Evaluation at 6 months was performed clinically in all 2200 patients with CT or MR Follow-up obtained in 420 patients while clinical follow-up evaluation at 18 months was available for 1400 patients (*table I*).

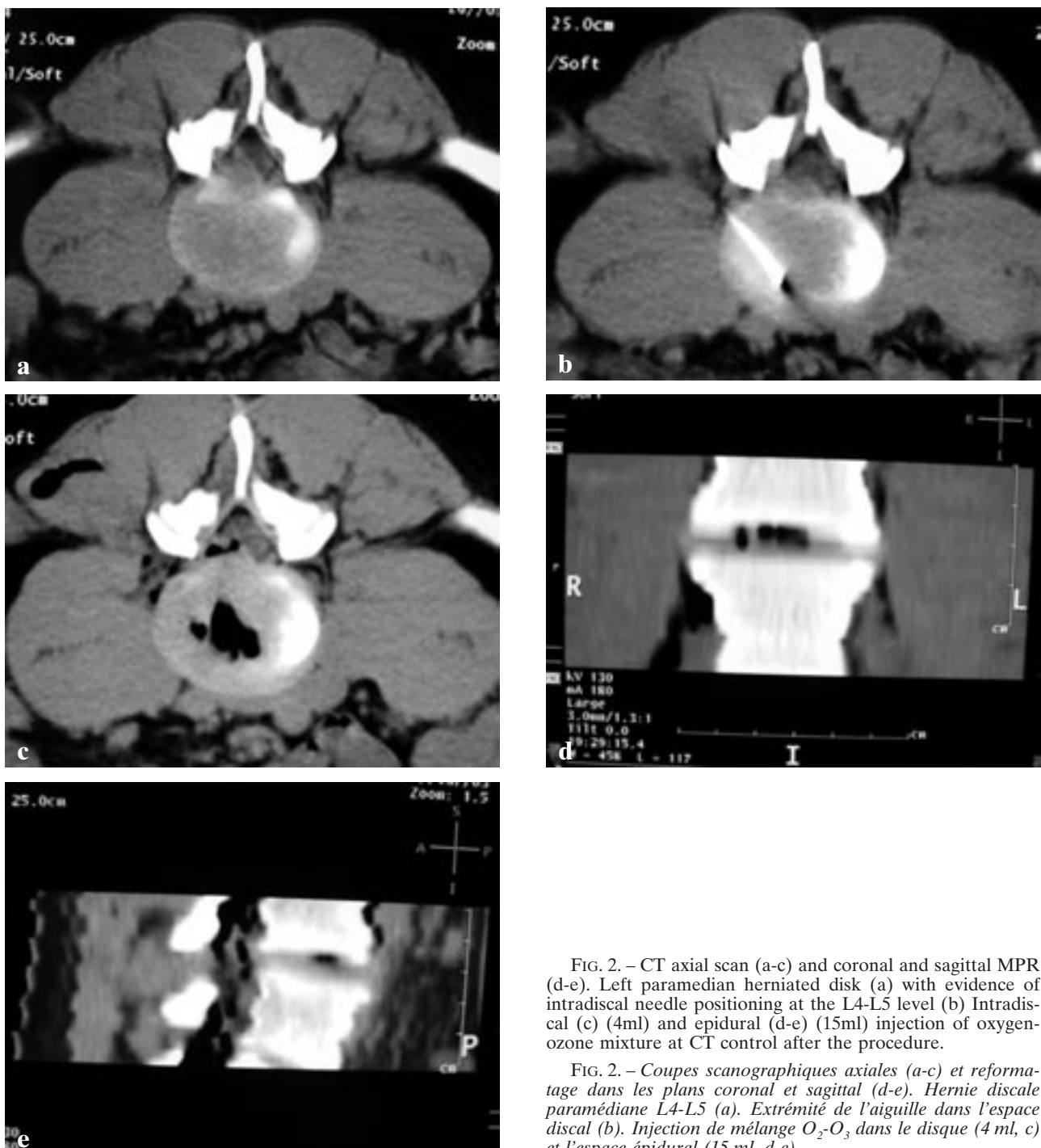


FIG. 2. – CT axial scan (a-c) and coronal and sagittal MPR (d-e). Left paramedian herniated disk (a) with evidence of intradiscal needle positioning at the L4-L5 level (b) Intradiscal (c) (4ml) and epidural (d-e) (15ml) injection of oxygen-ozone mixture at CT control after the procedure.

FIG. 2. – Coupes scanographiques axiales (a-c) et reformattage dans les plans coronal et sagittal (d-e). Hernie discale paramédiane L4-L5 (a). Extrémité de l'aiguille dans l'espace discal (b). Injection de mélange  $O_2-O_3$  dans le disque (4 ml, c) et l'espace épidual (15 ml, d-e).

TABLE I. – Modified Mac Nab method.  
TABLEAU I. – Méthode de Mac Nab modifiée.

Success	Failure
<b>Excellent</b> — disappearance of symptoms — complete recovery in working and sport activities	<b>Mediocre</b> — insufficient improvement of symptoms — periodic administration of drugs — limitations of physical activity
<b>Good</b> — occasional episodes of low back pain or sciatica	<b>No results</b> — no improvement — surgery required
<b>Fair</b> — improvement of symptoms — limitation of heavy physical activity	<b>Bad</b> — worsening of clinical situation — surgery required

## RESULTS

The results at 6 and 18 months are summarized in tables II and III.

Clinical follow-up for up to 18 months in 1400 patients confirmed persistent good outcome in 75% of cases. CT or MR follow-up was done in 420 patients, documenting a reduction in herniated disc size only in 63% of cases (figure 3). We analyzed the failures reported herein, focusing on possible technical errors to establish whether indications for treatment had been too broad or whether correlations exist between certain types of herniated disc, site of herniation, type of intervention and treatment failure.

Retrospective analysis of our failures disclosed that a successful outcome was much more unlikely in the presence of calcified herniated discs, herniations

associated with stenosis of the spinal canal and large extruded herniations.

## DISCUSSION

We know from the natural history of herniated disc that clinical symptoms tend to disappear in up to 50% of patients and the disc herniation can shrink at CT or MR scans within eight to nine months after the onset of back pain, but not all patients can wait so long before improve symptoms [5-14]. The short-term success rate after surgery for lumbosacral disc herniation is around 95-98% with a 2-6% incidence of true recurrence of herniation. This percentage decreases to around 80% in the long-term due to the onset of symptoms linked to Failed Back Surgery Syndrome (FBSS) characterised by recurrence and/

TABLE II. – Results at 6 month follow-up.  
TABLEAU II. – Résultats à six mois.

In patients with degenerative disease complicated by herniation: — excellent in 40% — good or fair in 40% — mediocre or bad in 20%
In patients with L4 L5 or L5-S1 herniated discs: — excellent in 64% — good or fair in 13% — mediocre or bad in 23%
In patients with multiple disc herniations: — excellent in 58% — good or fair in 11% — mediocre or bad in 31%
In FBSS patients: — excellent in 45% — good or fair in 20% — mediocre or bad in 35%.
In patients with calcified disc herniations: — excellent in 35% — good or fair in 20% — mediocre or bad in 45%
In patients with herniated disc associated with stenosis: — excellent in 25% — good or fair in 25% — mediocre or bad in 50%

TABLE III. – Results at 18 month follow-up.  
TABLEAU III. – Résultats à 18 mois.

In patients with degenerative disease complicated by herniation: — excellent in 40% — good or fair in 38% — mediocre or bad in 22%
In patients with L4 L5 or L5-S1 herniated discs: — excellent in 62% — good or fair in 14% — mediocre or bad in 24%
In patients with multiple disc herniations: — excellent in 56% — good or fair in 12% — mediocre or bad in 32%
In FBSS patients: — excellent in 43% — good or fair in 19% — mediocre or bad in 39
In patients with calcified disc herniations: — excellent in 33% — good or fair in 18% — mediocre or bad in 49%
In patients with herniated disc associated with stenosis: — excellent in 25% — good or fair in 25% — mediocre or bad in 50%

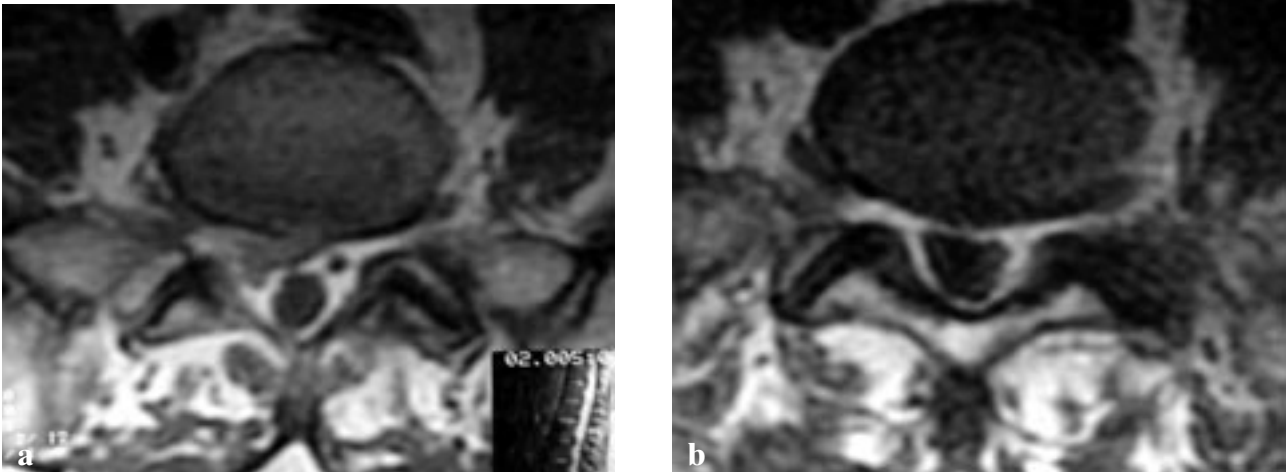


FIG. 3. – Follow-up MR of a patient treated at the L5-S1 level prior to (a) and 9 months after treatment (b).

FIG. 3. – *Hernie discale L5-S1 (a), examen effectué 9 mois après traitement (b).*

or hypertrophic scarring with severe symptoms in 20% of patients and FBSS proper in 15% [9, 10]. These figures have stimulated research into newer minimally-invasive techniques to improve clinical results. At the same time, advances in percutaneous techniques by interventional procedures (chemonucleolysis with chemopapain, nucleodisectomy introduced by Onik, IDET, disectomy LASER, and recently nucleoplasty) have minimized the invasive nature of surgical techniques and avoid or decreased complications such as postsurgical infection.

Reducing intervertebral disc size by mechanical aspiration of disc fragments or partially dissolving the herniation by drying reduces the conic pressure on the torn annulus and creates the space necessary for retropulsion whenever the circular fibres of the annulus regain a minimum capacity to contain the disc under tension.

All percutaneous procedures are mildly invasive entailing only a short hospital stay. By avoiding the spinal canal, these techniques also eliminate the risks of post-operative scarring linked to surgery which is often responsible for recurrence of pain. Percutaneous techniques can also be repeated in the same patient without precluding recourse to traditional surgery if they should fail. The success rates reported in different studies vary from 65 to 80% of excellent or good results with chemonucleolysis and aspiration [10]. Epidural steroid injections under CT or fluoroscopic guidance are also used to minimize radicular pain and to try to obtain complete pain relief [2, 4, 8, 15, 20, 21]. Discography is often used to decide regarding the possibility to perform percutaneous disectomy and chemonucleolysis but is useless in case of  $O_2-O_3$  therapy.

Chemonucleolysis with “nucleoptesis” combined with drying the nucleus with an oxygen-ozone mixture ( $O_2-O_3$ ) uses a colorless irritant gas with a pungent odour which is unstable and has a strong oxidizing power with good antiseptic, disinfectant and antiviral properties. Ozone is prepared and administered as required by transforming a small percentage of oxygen into ozone using special gener-

ators. The  $O_2-O_3$  gas mixture produced can be injected into the intervertebral disc and root foramina, 3-4 ml into the disc and 15-20 ml into the neural foramen and root canal. The concentration of the mixture is adjusted by the equipment. The dose mainly administered to treat disc disease is 30 micrograms/ml, a concentration calculated from experimental studies as the amount best suited to dry out the nucleus and minimize inflammation. A number of studies have been published in the literature on the  $O_2-O_3$  treatment of disc herniation with satisfactory results in selected cases [1, 3, 6, 7, 13, 18]. The causes of backache are the topic of scientific investigation. Mechanical and/or inflammatory irritation of the nerve endings is responsible for low back pain [11, 19, 20, 23, 24]. The natural response of any structure to injury is to trigger a repair process by means of an inflammatory response. The number of direct or immune-mediated inflammatory events accounts for decompressive FBSS in some patients.

#### Mechanism of action of the $O_2-O_3$ mixture

The nucleus pulposus can set off an immune-mediated inflammatory process as the proteoglycan component of its nucleus is segregated from the immune system after birth. Herniation of the nucleus pulposus would therefore trigger an autoimmune reaction, generating an inflammatory process whose cell component is mainly supported by macrophages. On the other hand, the nucleus pulposus can also give rise to an inflammatory process through a non-immune-mediated mechanism supported by the many inflammatory agents identified in its nucleus.

The reactive tissue surrounding the disc contains histiocytes, fibroblasts in the herniations, and chondrocytes in the disc protrusions able to produce cytokines (Interleukin-1 alpha, Interleukin 6 and TNF-alpha) with an increase in phospholipase A2 leading to the release of prostaglandin E2, leukotrienes and thromboxanes found in larger quantities in non-contained discs hernia-

tions and patients presenting more severe symptoms.

Prostaglandins cause pain. In small amounts, they enhance sensitivity of the nerve roots and other pain-producing substances like bradykinin. Experimental studies have shown that an oxygen-ozone gas mixture at the concentrations used for intradiscal treatment have the same effect as steroids on inhibiting cytokine production and hence the pain induced by the same [12].

The oxygen-ozone mechanisms of action are currently being investigated and include:

1) enhanced oxygenation and reduced inflammation in the disease site due to the oxidizing effect on pain-producing mediators;

2) direct effect of ozone on the mucopolysaccharides making up the nucleus pulposus of the intervertebral disc with rupture of water molecules and shrinkage of the disc exerting compression on the nerve roots;

3) improved microcirculation due to resolution of venous stasis and lack of oxygenated blood supply following mechanical compression of the herniated disc and disc protrusion on the vessel components.

### Tissue structure alterations

In vivo experimental studies on swine intervertebral discs and in vitro tests on human discs with intradiscal administration of an O<sub>2</sub>-O<sub>3</sub> mixture at a concentration of 27mcg/ml demonstrated dehydration of the fibrillary matrix of the nucleus pulposus disclosing the collagen mesh/network and regressive events (fragmentation and vacuole formation). Neoangiogenesis was sometimes present with mild hyperplasia of the chondrocytes in the matrix periphery. Such changes are thought to be due to the decomposition of ozone with release of free radicals which act directly on the disc matrix or indirectly via proteolytic enzymes.

### Complications and risks

No early or late neurological or infectious complications have been reported following O<sub>2</sub>-O<sub>3</sub> injection. The results are virtually the same as those of other percutaneous techniques (75-80% success rate), injections can be repeated if necessary, and there are no side effects. However, the low costs of this O<sub>2</sub>-O<sub>3</sub> therapy make this the method of choice in the percutaneous treatment of herniated lumbar disc.

### CONCLUSION

In our experience, intradiscal O<sub>2</sub>-O<sub>3</sub> treatment of herniated lumbar disc has revolutionized the percutaneous approach to nerve root disease making it safer, cheaper and easier to repeat than treatments currently in use. In addition, O<sub>2</sub>-O<sub>3</sub> therapy does not preclude later recourse to surgery should patients fail to benefit. The technique is also reliable and compatible with other percutaneous procedures.

O<sub>2</sub>-O<sub>3</sub> treatment also has the advantage of being feasible in virtually all patients with root syndromes

without the contraindications of chemonucleolysis or nucleosuction which must be ruled out by discography.

In our experience the failure has been mostly related to patients with spinal canal stenosis, recurrent herniated disk, calcified herniated disk and small descending herniated disk of the lateral recess with significant compression of the nerve sheath.

On the basis of our results and the assessment of our failures, we recommend careful selection patients to avoid broadening the indications for treatment, thereby ensuring a high success rate.

Accurate diagnosis of the lesion and the spinal level to be treated, accurate technique under CT or fluoroscopic guidance in expert hands and patient follow-up by the neuroradiologist after treatment are key factors in ensuring the successful outcome of percutaneous treatment for this common condition.

### REFERENCES

- [1] ANDREULA C. Lumbar Herniated disk and degenerative changes. Interventional spinal treatment with chemiodiscolysis with nucleolysis with O<sub>3</sub> and perigangliar infiltration in 150 cases. *Rivista di Neuroradiologia* 2002; 14: 81-88.
- [2] BERGER O, DOUSSET V, DELMER O, POINTILLART V, VITAL JM, CAILLE JM. evaluation of the efficacy of foraminal infusions of corticosteroids guided by computed tomography in the treatment of radicular pain by foraminal injection. *J Radiol Sep* 1999; 80: 917-925.
- [3] BONETTI M, COTTICELLI B *et al.* Oxygen-ozone therapy vs epidural steroid injection. *Rivista di Neuroradiologia* 2000; 13: 203-206.
- [4] BUCHNER M, ZEIFANG F, BROCAI DR, SCHILTENWOLF M. Epidural corticosteroid injection in the conservative management of sciatica. *Clin Orthop* 2000; 375: 149-156.
- [5] BUSH K, COWAN N, KATZ DE, GISHEN P. The natural history of sciatica associated with disc pathology. A prospective study with clinical and independent radiologic follow-up. *Spine* 1992; 17: 1205-1212.
- [6] D'ERME M, SCARCHILLI A *et al.* Ozone therapy in lumbar sciatic pain. *Radiol Med* 1999; 95: 21-24.
- [7] FABRIS G, TOMMASINI G *et al.* Oxigen-ozone therapy in percutaneous treatment of lumbar HNP. *Rivista di Neuroradiologia* 1999; 12: 23.
- [8] FURMAN MB, O BRIEN EM, ZGLESZEWSKI TM. Incidence of intravascular penetration in transforaminal lumbosacral epidural steroid injection. *Spine* 2000; 25: 2628-2632.
- [9] GALLUCCI M, SPLENDIANI A, MASCIOCCHI C. Spine and spinal cord: neuroradiological functional anatomy. *Rivista di Neuroradiologia* 1997; 11: 293-304.
- [10] GANGI A, DIETEMANN JL, MORTAZAVI R, PFLEGER D, KAUFF C, ROY C. CT-guided interventional procedures for pain management in the lumbosacral spine. *RadioGraphics* 1998; 18: 621-633.
- [11] HANG JD, GEORGESCU HI *et al.* Herniated lumbar intervertebral disc spontaneously produce matrix metallo proteinases, nitric oxide, interleukin 6 and prostaglandin E2. *Spine* 1996; 21: 271-277.
- [12] ILIAKIS E. Ozone treatment in low back pain. *Orthopaedics* 1995; 1: 29-33.
- [13] LEONARDI M, BARBARA C *et al.* Percutaneous treatment of lumbar herniated disk with intradiscal injection of ozone mixture. *Rivista di Neuroradiologia* 2001; 14: 51-53.
- [14] LONG MD. Decision making in lumbar disc disease. *Clinical Neurosurg* 1991; 39: 36-51.
- [15] LOWELL TD, ERRICO TJ, ESKENAZI MS. Use of epidural steroids after discectomy may predispose to infection. *Spine* 2000; 25: 516-519.

- [16] MELZACK R. The McGill Pain Questionnaire: Major properties and scoring system. *Pain* 1975; 1: 277-299.
- [17] MUTO M, DE MARIA G, IZZO R, FUCCI G, APRILE I. Nondiscal lumbar radiculopathy: combined diagnostic approach by CT and MR. *Rivista di Neuroradiologia* 1997; 10: 165-173.
- [18] MUTO M, AVELLA F. Percutaneous treatment of herniated lumbar disc by intradiscal oxygen-ozone injection. *Interventional Neuroradiology* 1998; 4: 279-286.
- [19] OYSTEIN PN, SVEIN IM, OSTERUD B. The inflammatory properties of contained and non-contained lumbar disc herniation. *Spine* 1997; 22: 2484-2488.
- [20] SAAL J. The role of inflammation in lumbar spine. *Spine* 1995; 20: 1821-1827.
- [21] SCHMID G, VETTER S, GOTTMANN D, STRECKER EP. CT-guided epidural/perineural injection in painful disorders of the lumbar spine: short and extended term results. *Cardiovasc Intervent Radiol* 1999; 22: 493-498.
- [22] WEINSTEIN SM, HERRING SA, DERBY R. Contemporary concepts in spine care. Epidural steroid injection. *Spine* 1995; 20: 1842-1846.
- [23] WEINSTEIN J. Mechanism of spinal pain: the dorsal root ganglion and its value as a mediator of low back pain. *Spine* 1986; 11: 999-1001.
- [24] ZENNARO H, DOUSSET V, VIAUD B, ALLARD M, DEHAIS J, SENEGAS J, CAILLE JM. Periganglionic foraminal steroid injections performed under CT control. *AJNR* 1998; 19: 349-352.

## Analyse de livre

### **“Diffusion-Weighted MR Imaging of the Brain”, T. MORITANI, S. EKHOLM, P.-L. WESTESSON, 2004, ISBN 3-540-03439-0**

L'imagerie de diffusion est aujourd'hui une des techniques-clé de l'exploration du système nerveux central. Largement utilisée pour le diagnostic des accidents ischémiques à la phase aiguë, son application s'étend à beaucoup d'autres affections. L'ouvrage très pratique de T. Moritani, S. Ekholm, P.L. Westesson, souligne l'intérêt de cette séquence d'imagerie rapide. Les premiers chapitres sont consacrés aux bases techniques de l'imagerie de diffusion, bénéficiant d'illustrations en couleur très utiles à la compréhension de ces données, aux résultats normaux, ainsi qu'aux

artéfacts observés. Les chapitres suivants sont consacrés à la pathologie cérébrovasculaire, aux affections démyélinisantes, dégénératives, toxiques et métaboliques, aux infections crâniocérébrales et à la pathologie tumorale. Deux thèmes spécifiques sont abordés dans des chapitres distincts : l'épilepsie et la neuro-imagerie de l'enfant. L'ouvrage se conclut par un chapitre particulièrement utile à l'imagerie de diffusion ; celui-ci est fait de tableaux illustrés, où sont classées les affections en fonction du signal observé en diffusion, en T2 et de la valeur de l'ADC. Les auteurs proposent un ouvrage de très grande qualité, parfaitement illustré, pratique, indispensable à tout spécialiste amené dans sa pratique à utiliser l'IRM de diffusion.